Benign bone Neoplasms

Osteoma

- Osteomas are benign tumors composed of mature compact or cancellous bone.
- The majority of cases are seen in young adults. It is generally asymptomatic, solitary lesions, or it could be an incidental finding in radiographic evaluation of the jaw for other problems.
- The lesion may arise on the surface of the bone, as a polypoid or sessile mass “periosteal osteoma”, or may be located in the medullary bone “endosteal osteoma”.

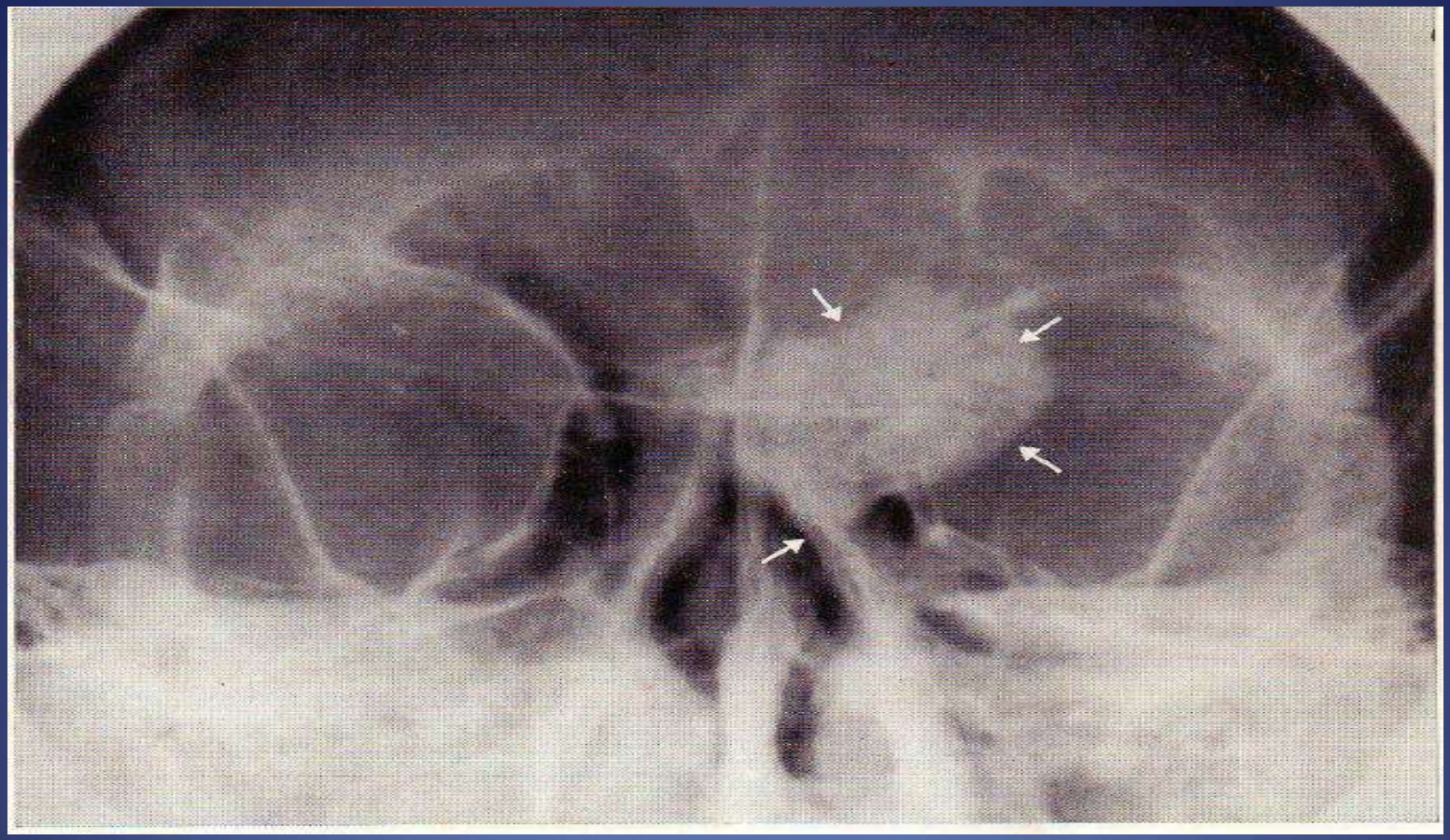

Osteoma :Male ,36 years ,ethmoid sinus ,Typically osteoma appears as a dense, opaque, sharply demarcated mass that is usually broad based and ranges from 1 cm. to 8.5 cm. in diameter.

Histopathologic Features

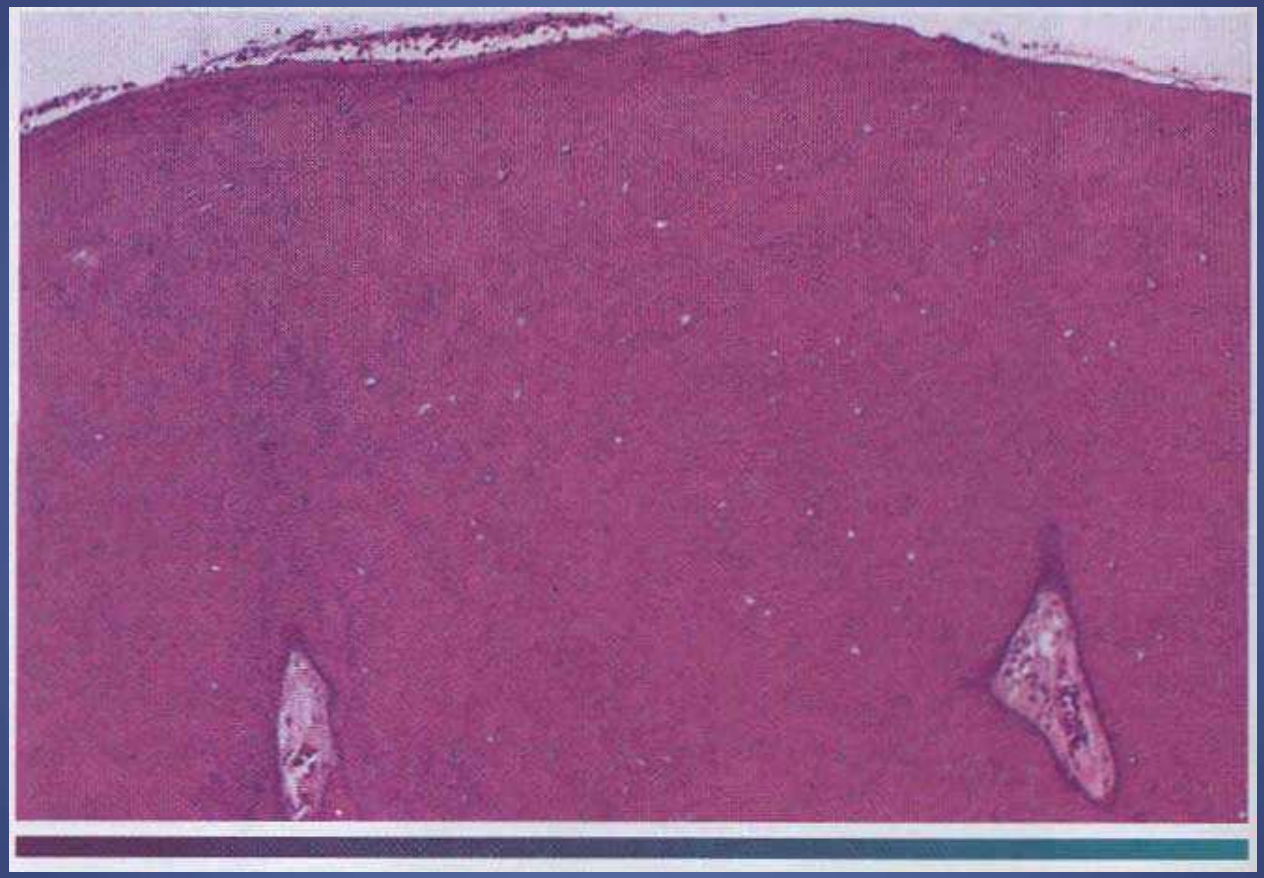

compact osteoma which composed of dense bone with only minimal marrow elements.

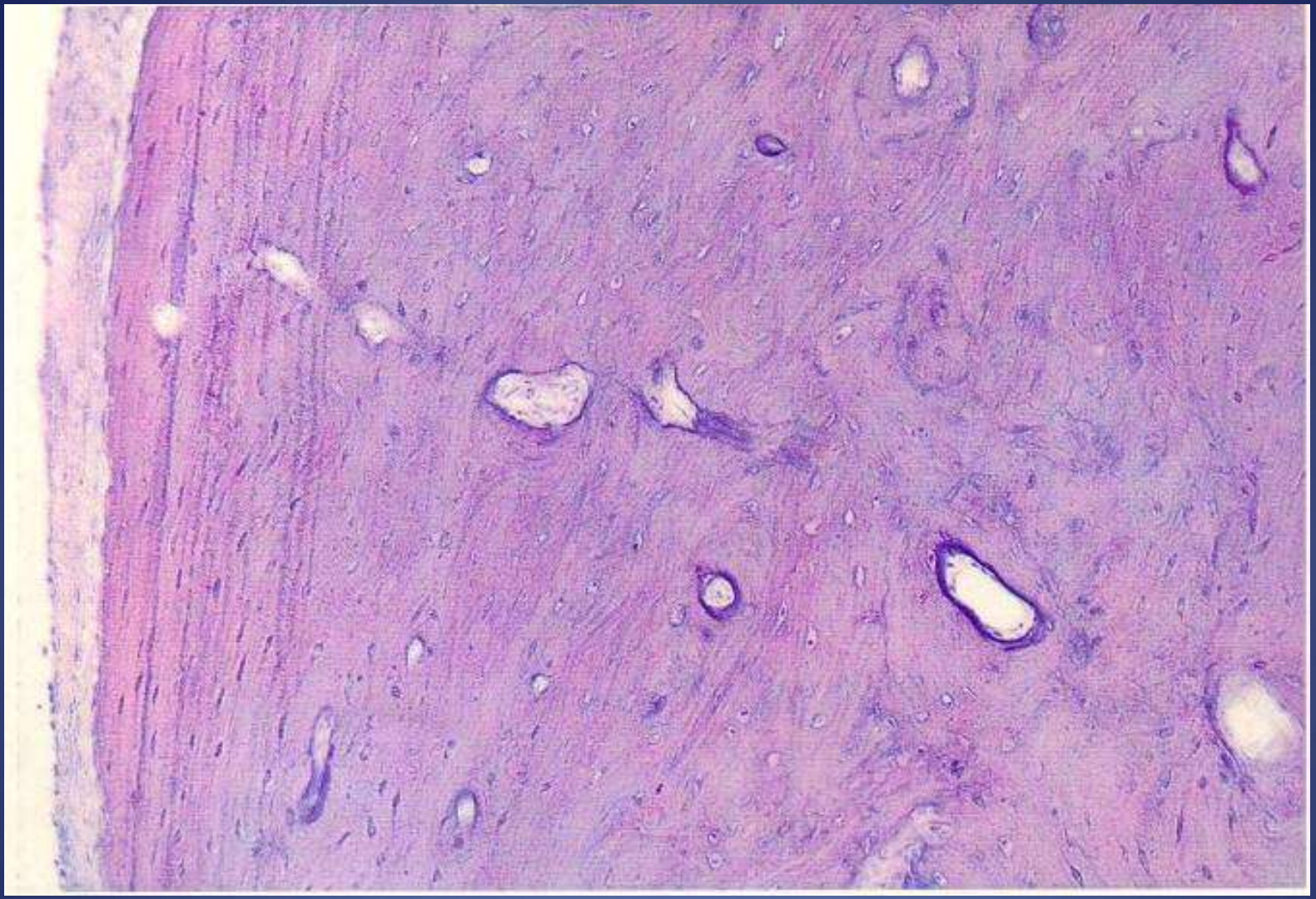

Compact osteoma

hard, dense, compact lamellar bone, similar to cortical bone, in which haversian systems are present. These so-called ivory or compact osteomas have little stroma, and that which is present consists of bland fibrous tissue

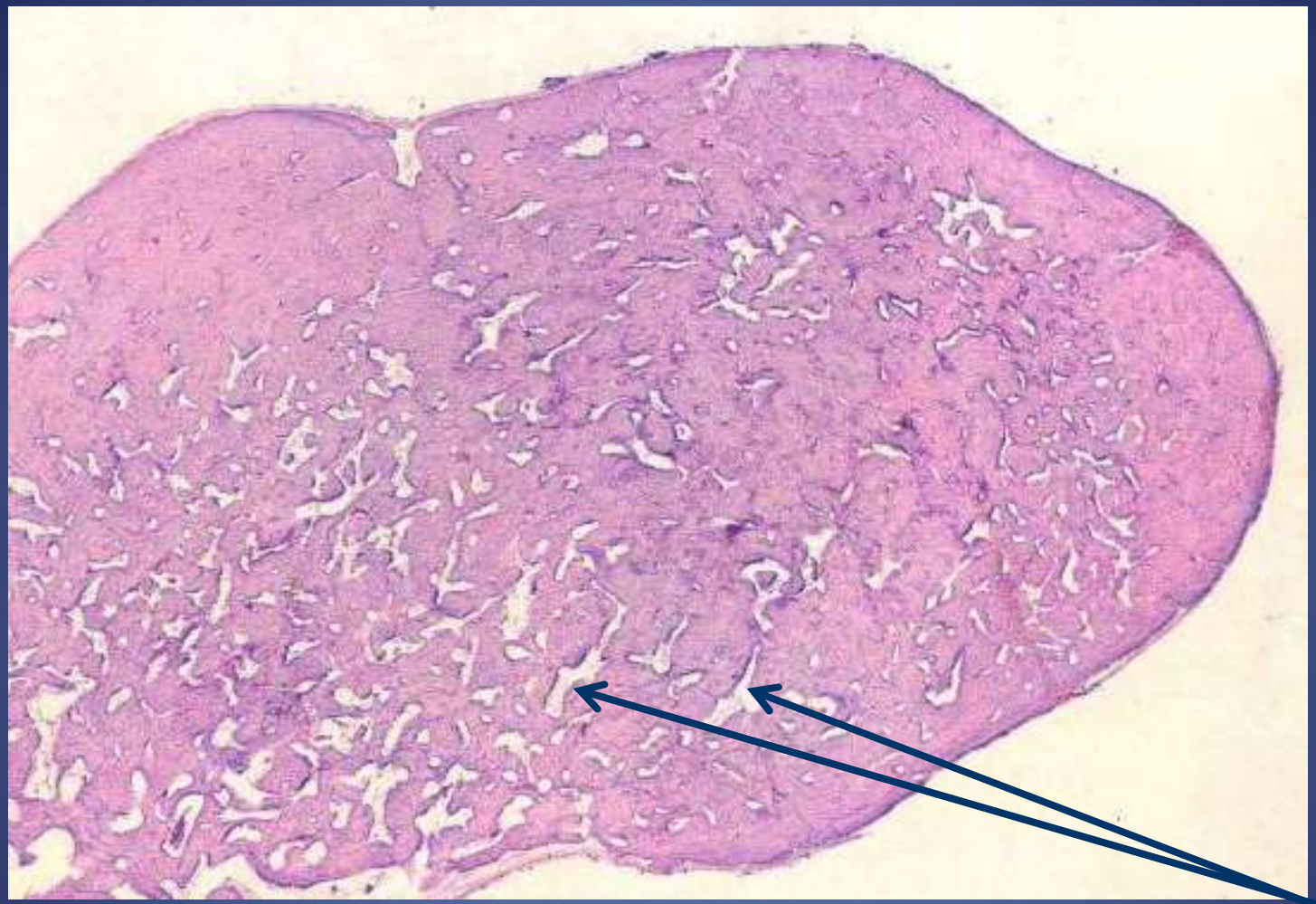

Cancellous osteoma in frontal sinus

composed predominantly of mature lamellar trabecular bone between which fat and marrow elements are found

Gardner Syndrome

- a rare disorder that is inherited as an autosomal dominant trait.
- characterized by:

1. adenomatous polyps of the large bowel
2. multiple osteomas of the skull and mandible,
3. multiple keratinous cysts of the skin
4. soft tissue neoplasms especially fibromatosis. Most of the fibromatoses are intra-abdominal and develop following surgical intervention.

Gardner syndrome. Panoramic radiograph showing multiple osteomas of the mandible. (About 90% of patients demonstrate skeletal abnormalities)

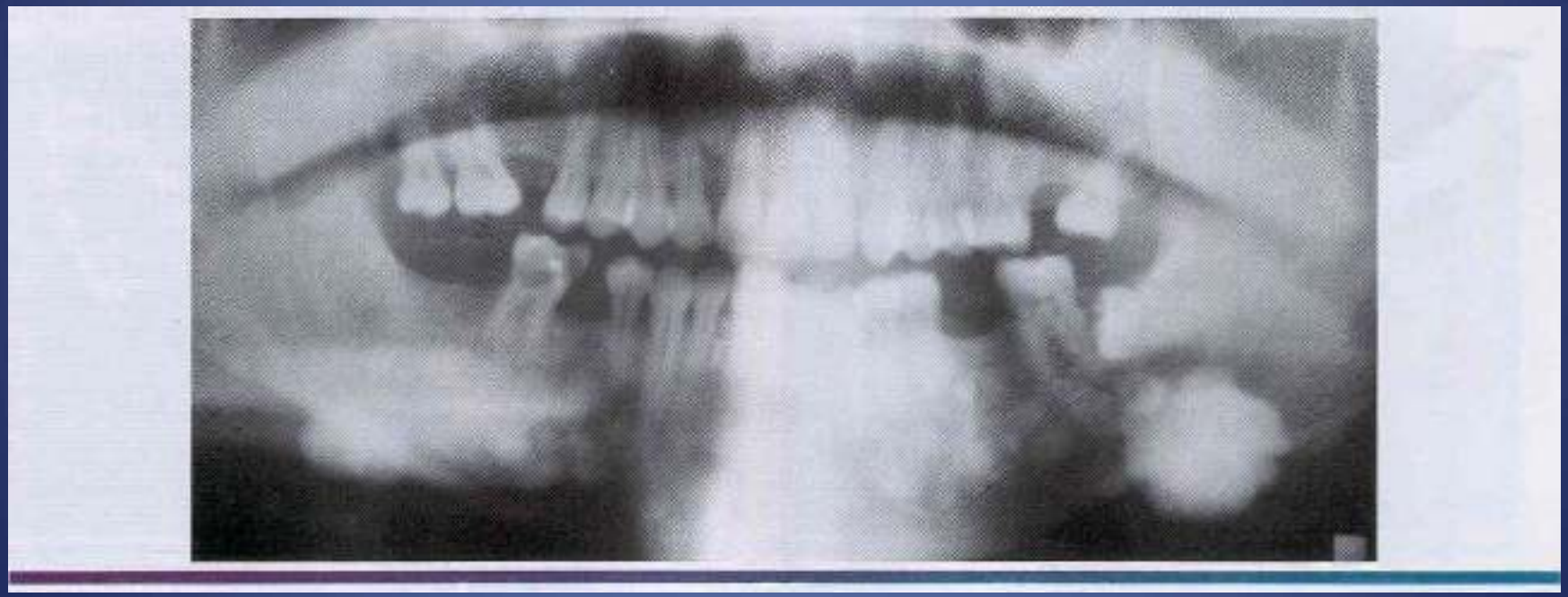

Osteomas of Gardner's syndrome.

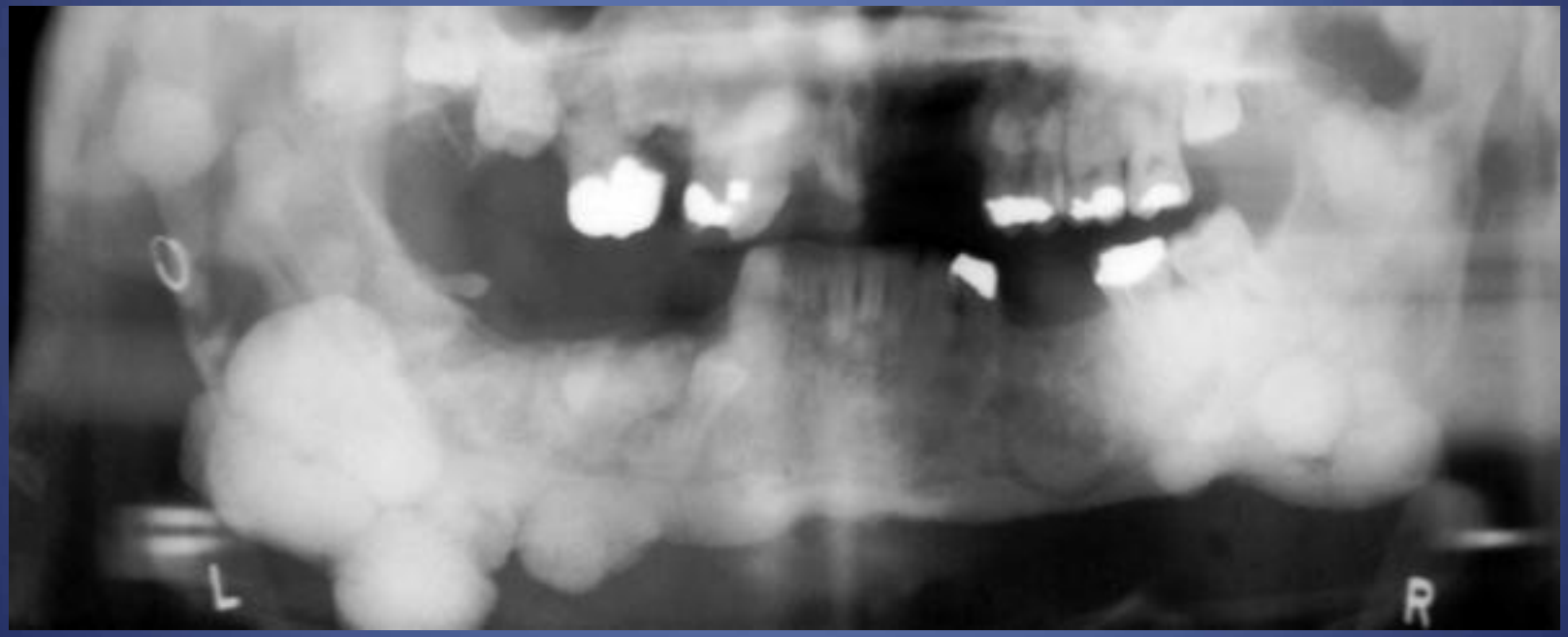

Gardner syndrome . A segment of resected large bowel showing polyp formation *(arrow)* .

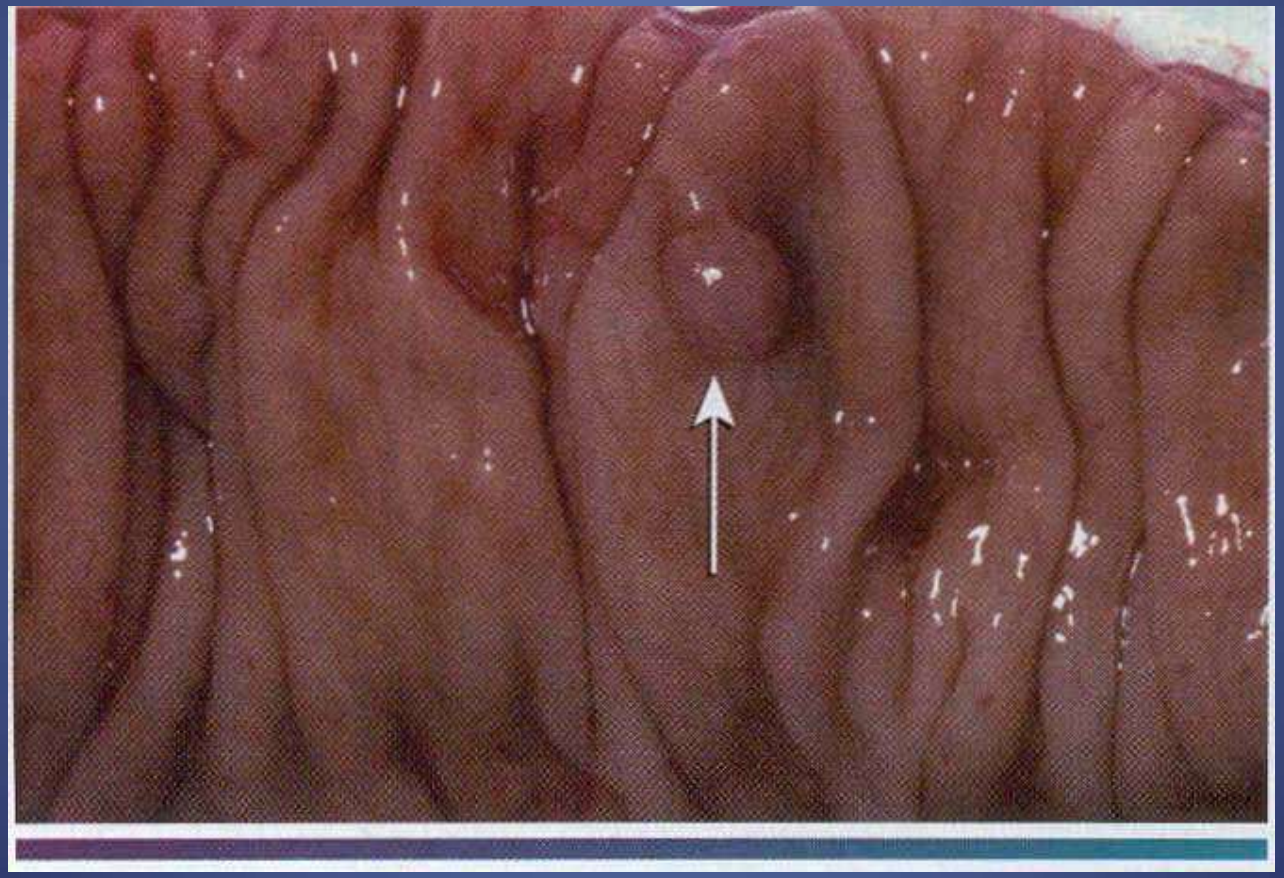

Gardner syndrome. This patient has multiple, large epidermoid cysts.

Osteoid osteoma

- a benign bone neoplasm ,very rare in the jaw bone. the typical finding is a radiolucent central nidus that is seldom larger than 1.5 cm. and that may, or may not, contain a dense center. This nidus is surrounded by a peripheral sclerotic reaction that may extend for several centimeters.

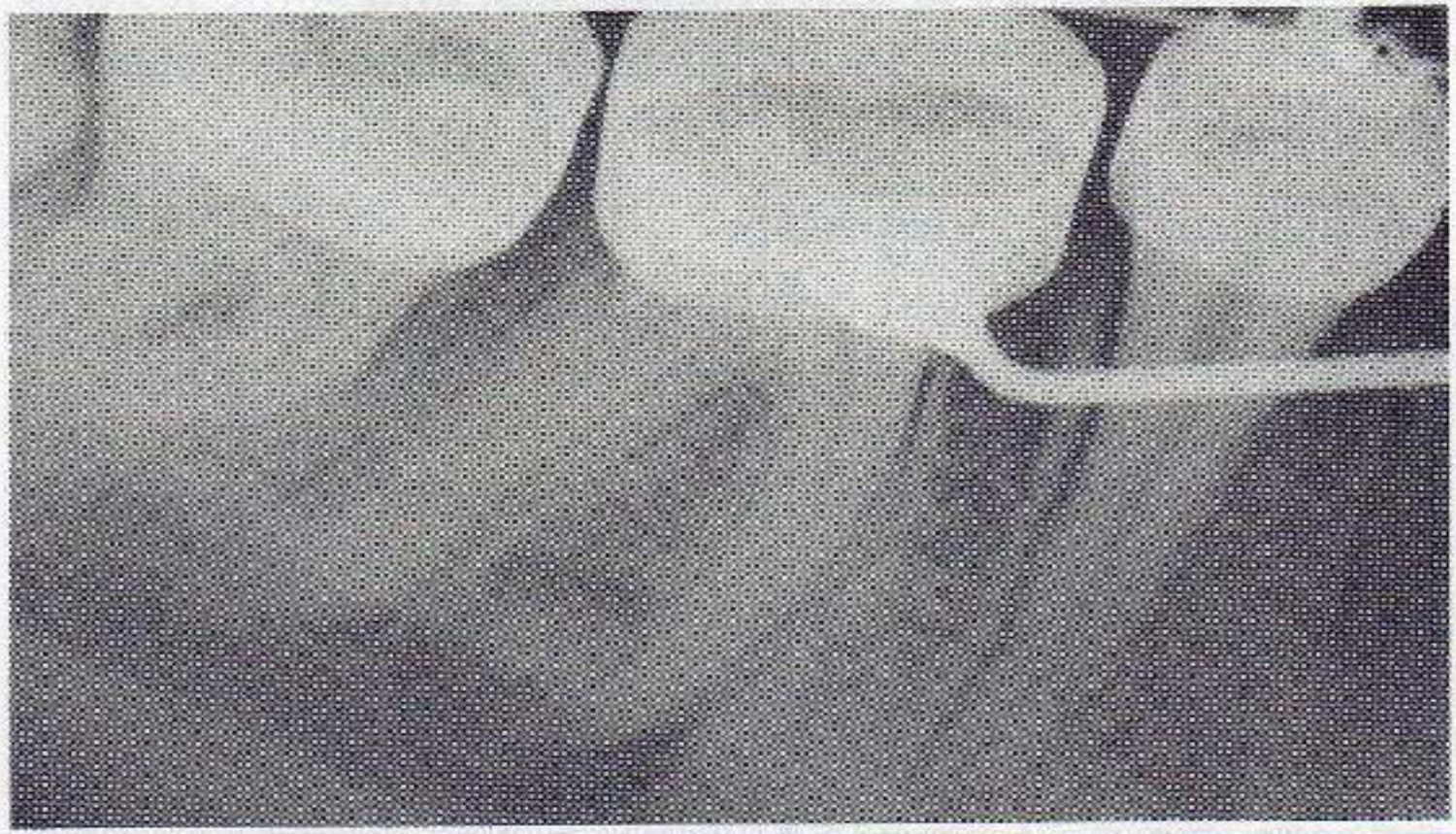

Figure 14-64 • Osteoid osteoma. A circumscribed, mixed radiolucent and radiopaque lesion near the apex of mesial root of mandibular first molar. The patient had dull, nocturnal pain that was relieved by aspirin. (Courtesy of Dr. Ellen Eisenberg.)

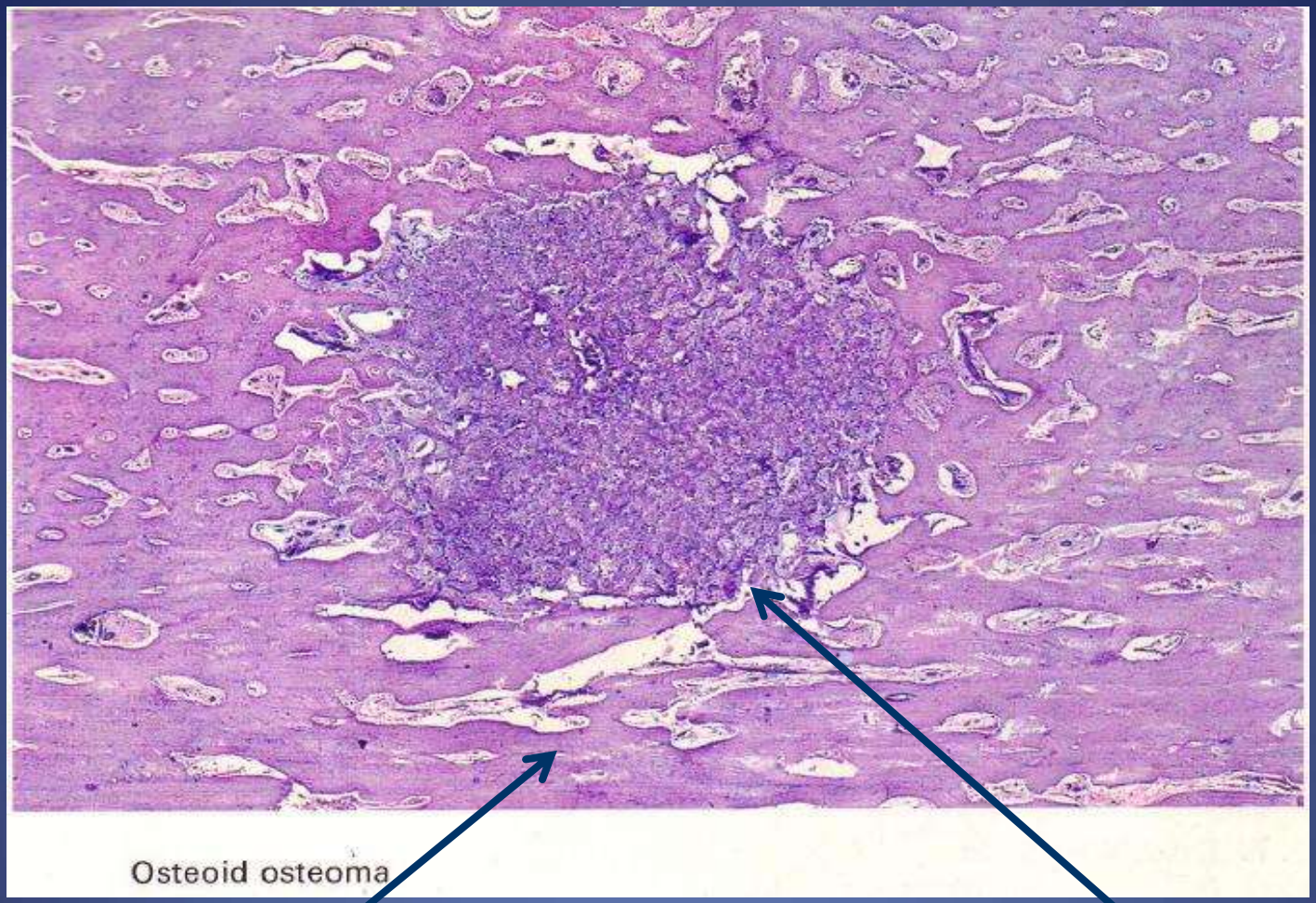

reactive bone formation

Central nidus

<2 cm

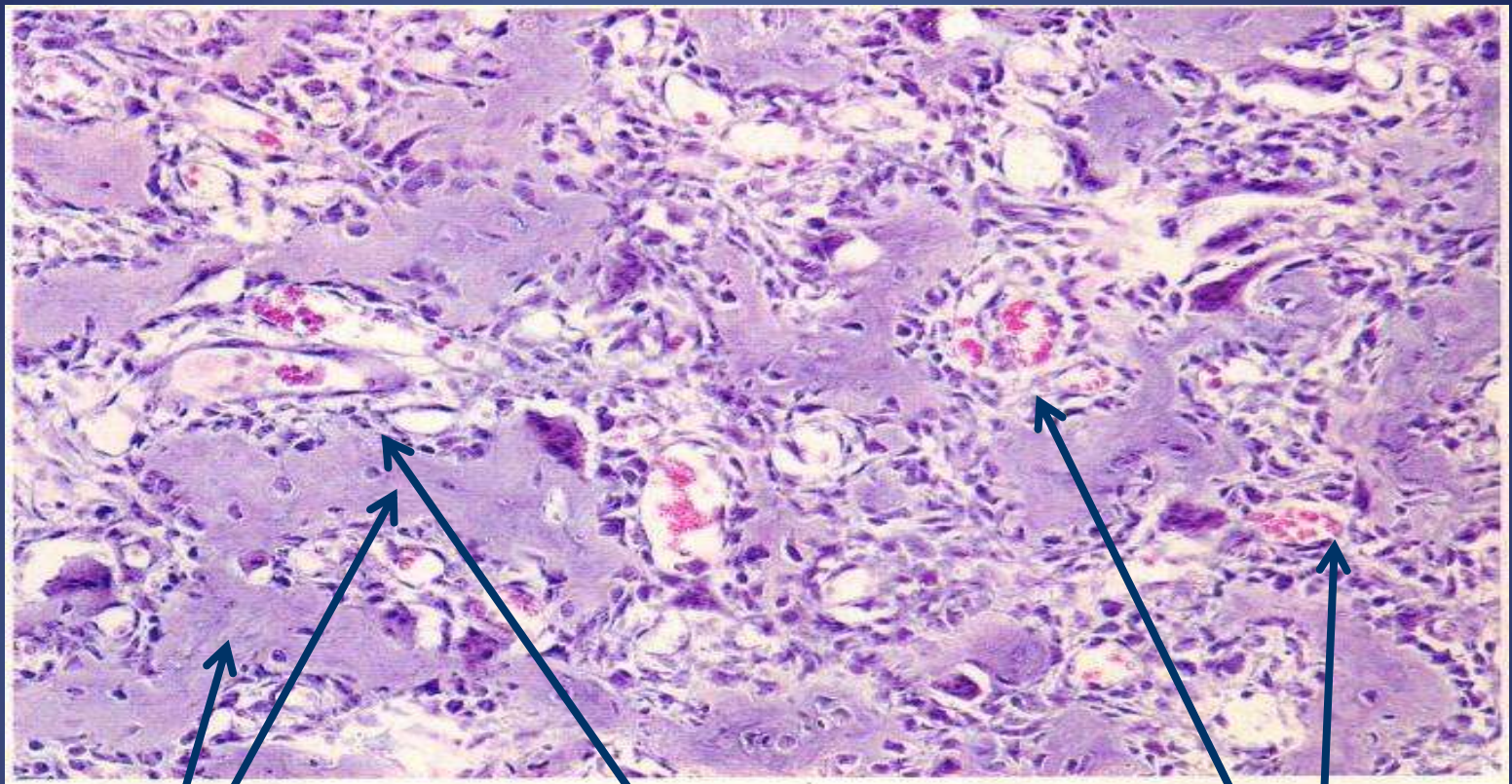

Fig. 6. Osteoid osteoma

Osteoid

osteoblasts

highly vascularized connective tissue

Osteoblasoma "Giant osteoid Osteoma"

- is a tumor closely related to osteoid osteoma both microscopically and ultrastructurally.
- It is distinguished from the osteoid osteoma by the larger size of the nidus, the absence or inconspicuousness of a surrounding area of reactive bone formation.

Because of the significant similarities between oseoblastoma and cementoblastoma some consider them to be identical, with one primary difference, which is fusion of the lesion to a tooth or not.

Figure 14-67 • **Cementoblastoma.** Low-power photomicrograph showing the tumor attached to the roots of the tooth.

Figure 14-66 • **Cementoblastoma. A,** A densely mineralized mass is seen at the apex of the distal root of the first molar. The root is partially resorbed. **B,** The surgical specimen shows that the mass is attached to the root. (Courtesy of Dr. John Wright.)

Figure 14-63 • Osteoblastoma. Computed tomography (CT) image showing a large, destructive radiolucent and radiopaque lesion of the mandible. (Courtesy of Dr. Ed Marshall.)

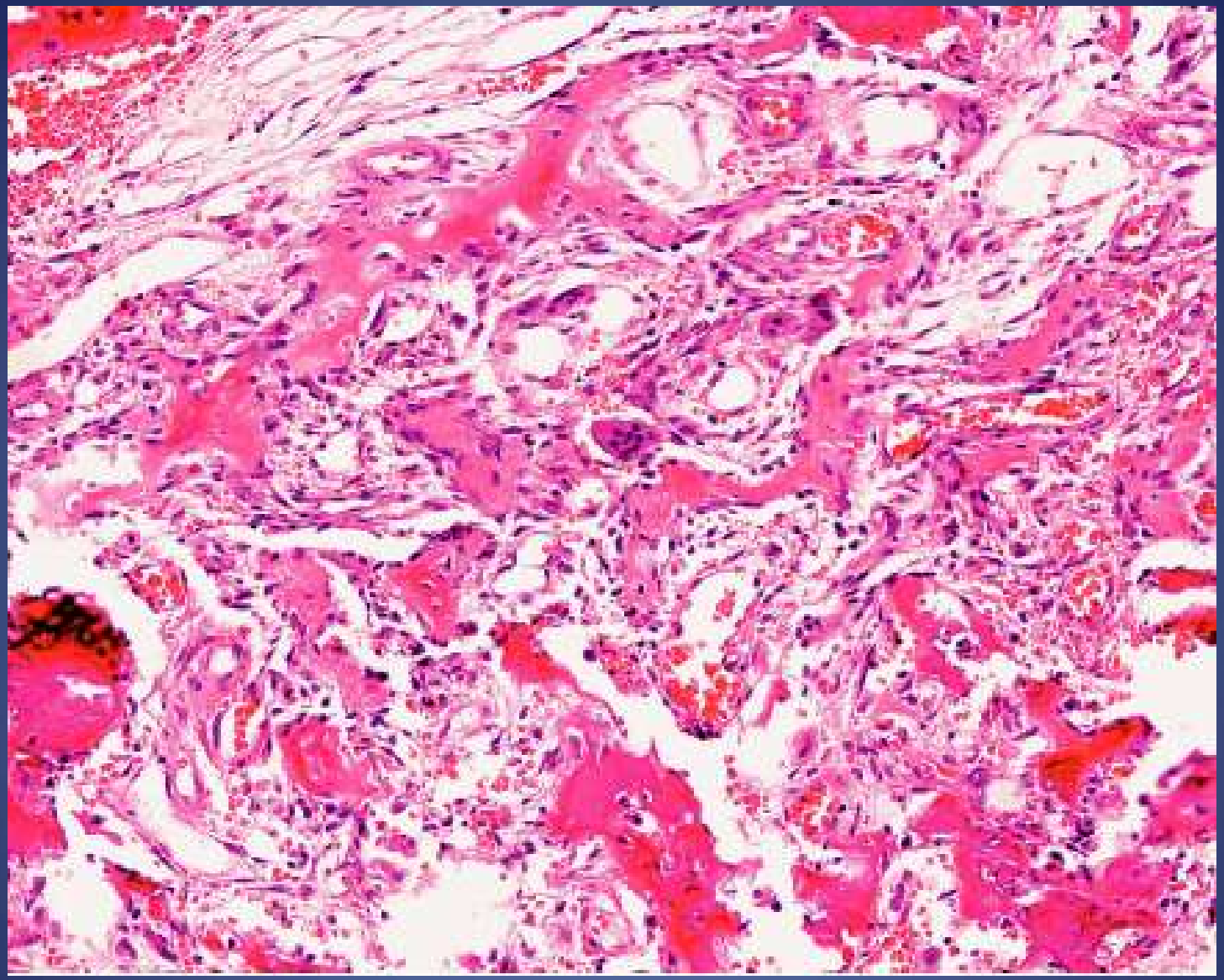

Osteoblastoma. Numerous neoformed osteoid trabeculae are lined .by osteoblasts and separated by a highly vascularized matrix

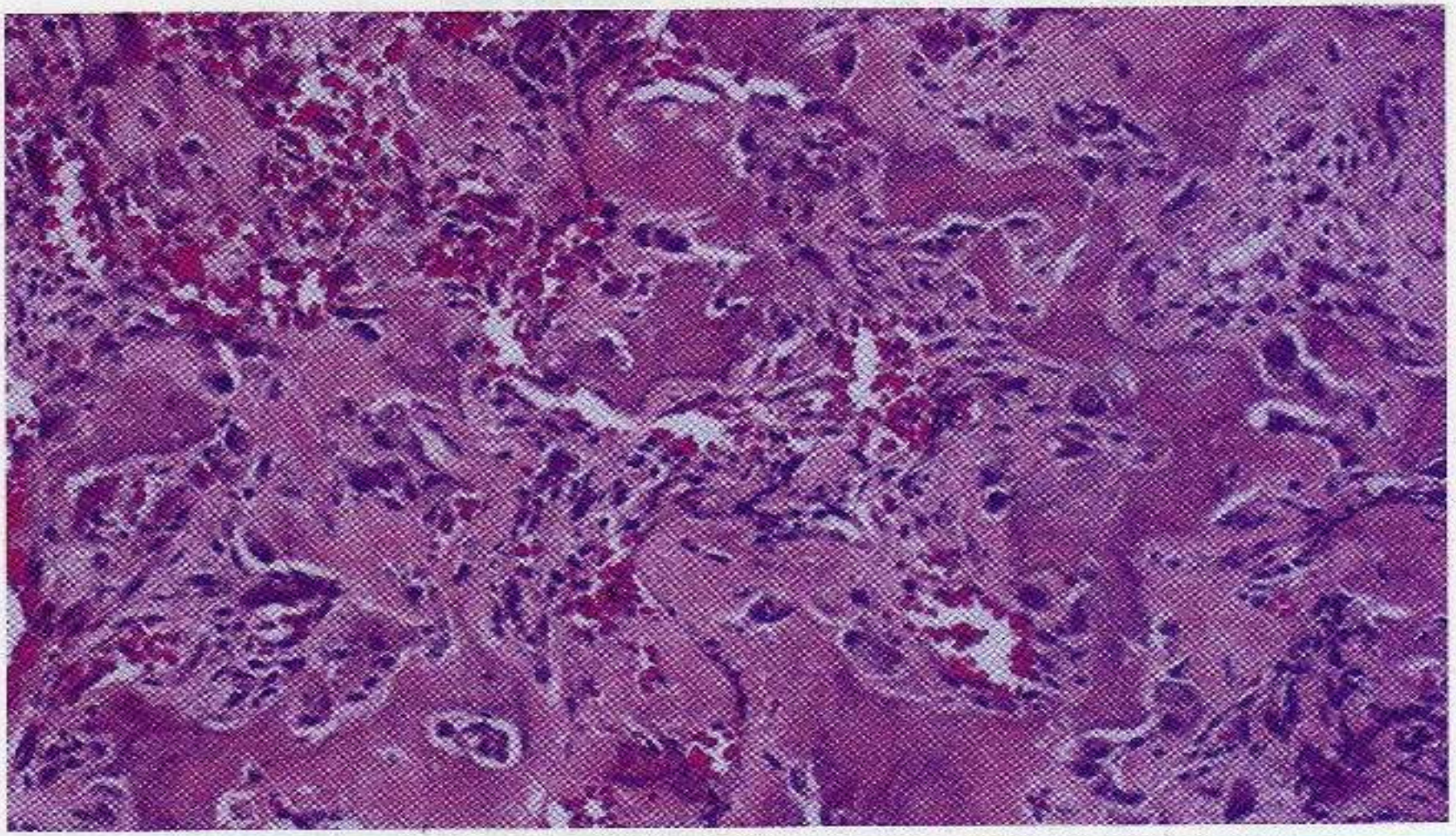

Figure 14-65 ◆ **Osteoblastoma.** High-power photomicrograph showing irregular bony trabeculae with prominent osteoblastic rimming and osteoclasts.

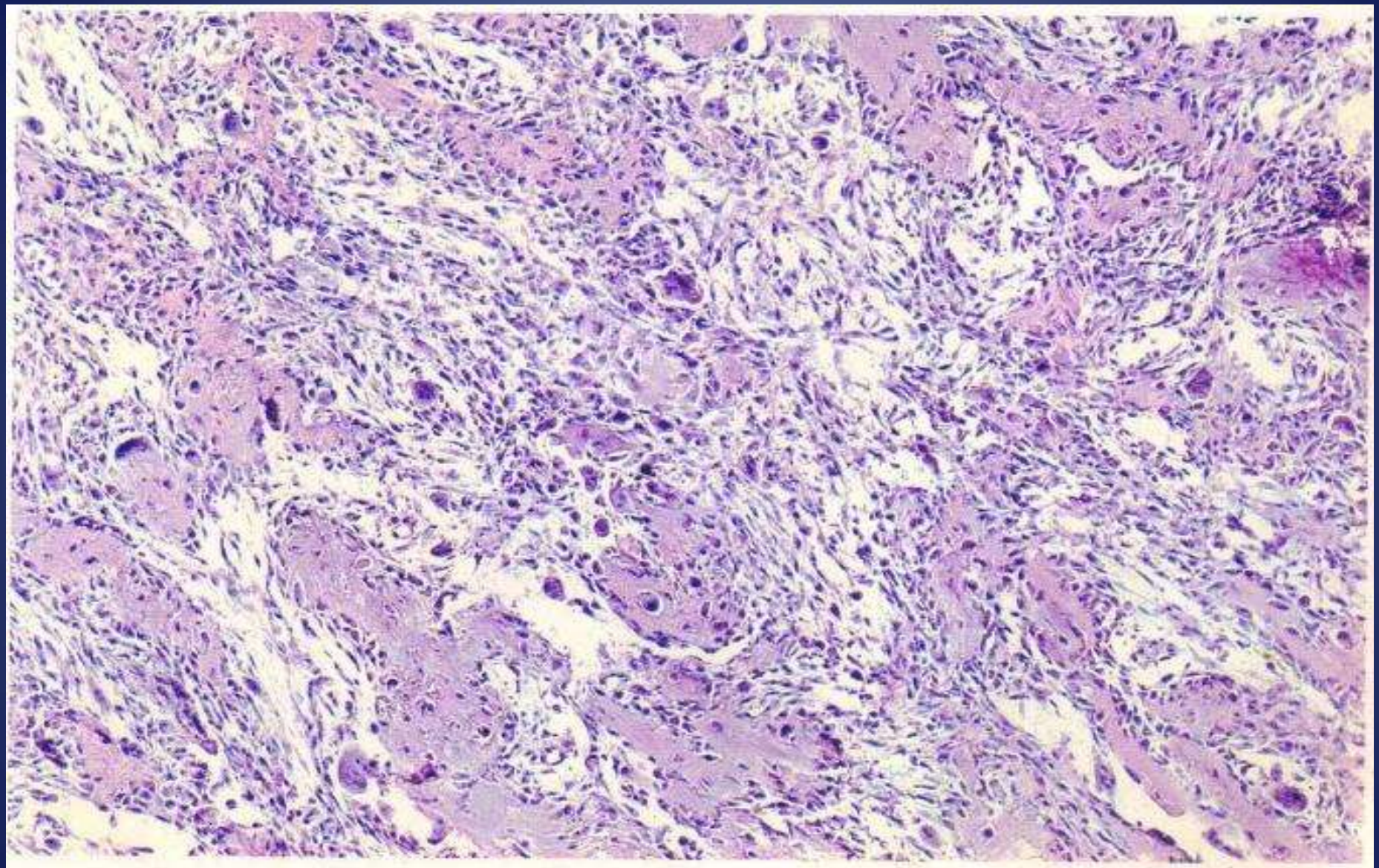

Fig. 10. Osteoblastoma
Same case as Fig. 9A

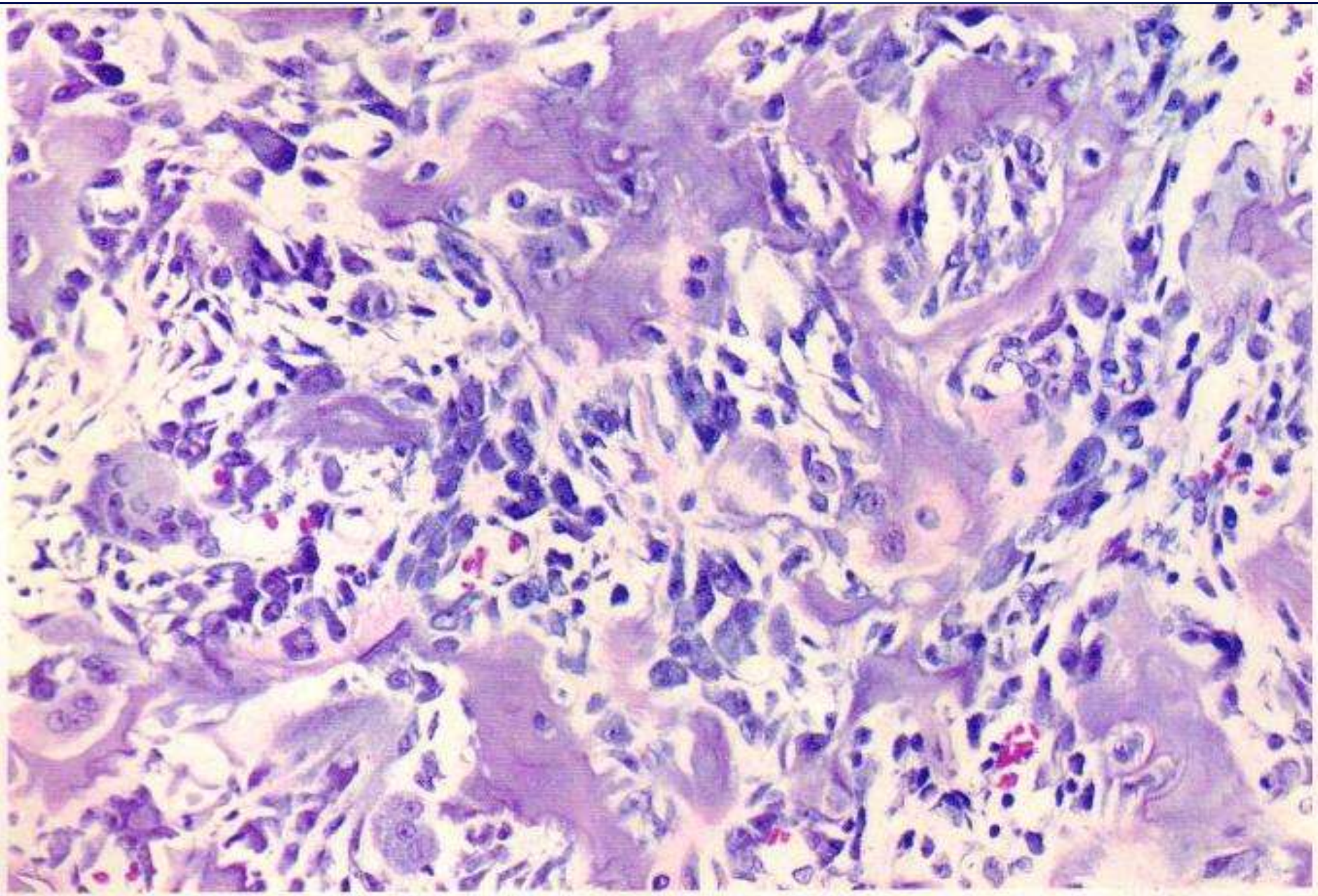

Fig. 12. Osteoblastoma
Same case as Fig. 9B

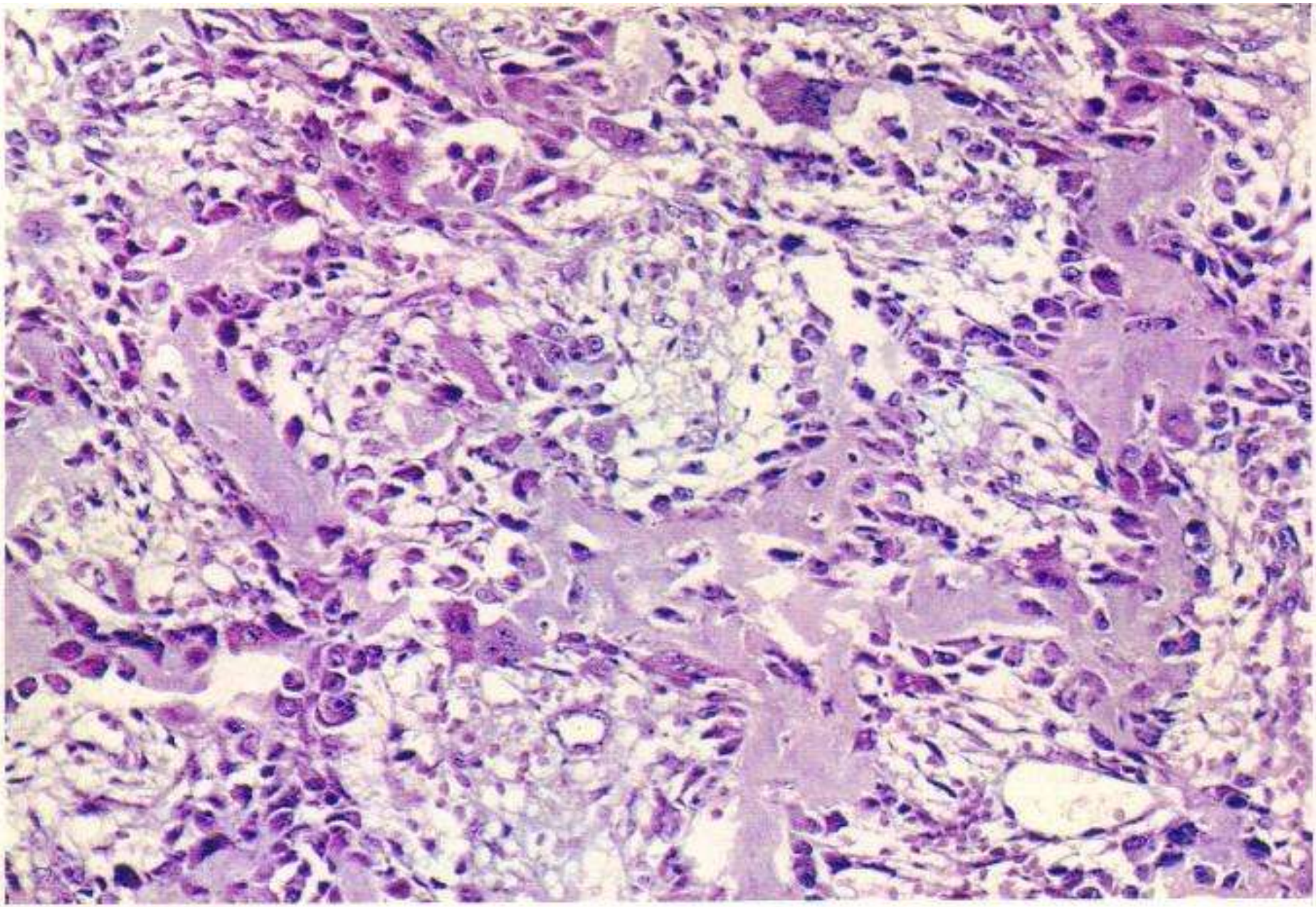

Fig. 11. Osteoblastoma
Same case as Fig. 9B

Desmoplastic fibroma. Microscopic differential diagnosis included fibrosarcoma.

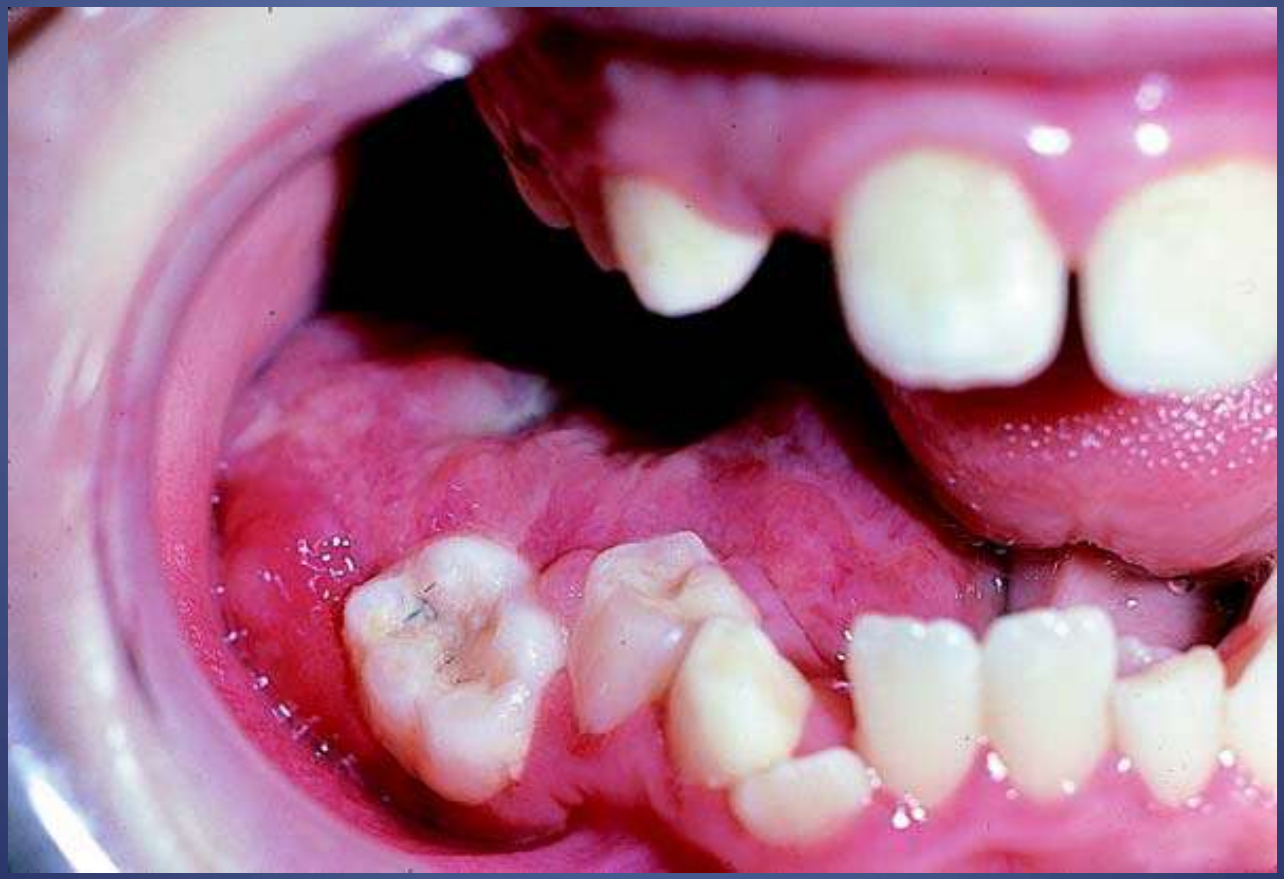

Desmoplastic fibroma. Note evenly distributed and benign-appearing fibroblasts in collagenous stroma.

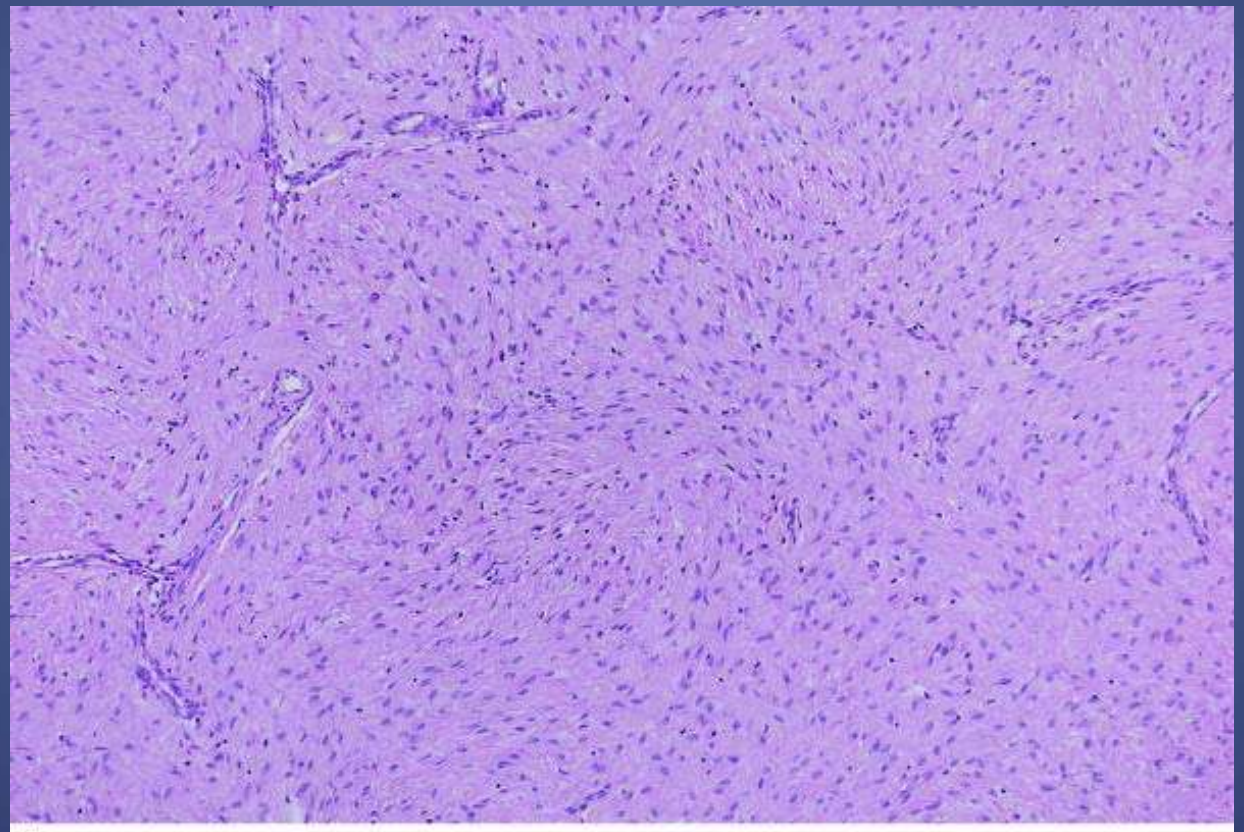

Desmoplastic fibroma. Note evenly distributed and benign-appearing fibroblasts in collagenous stroma.

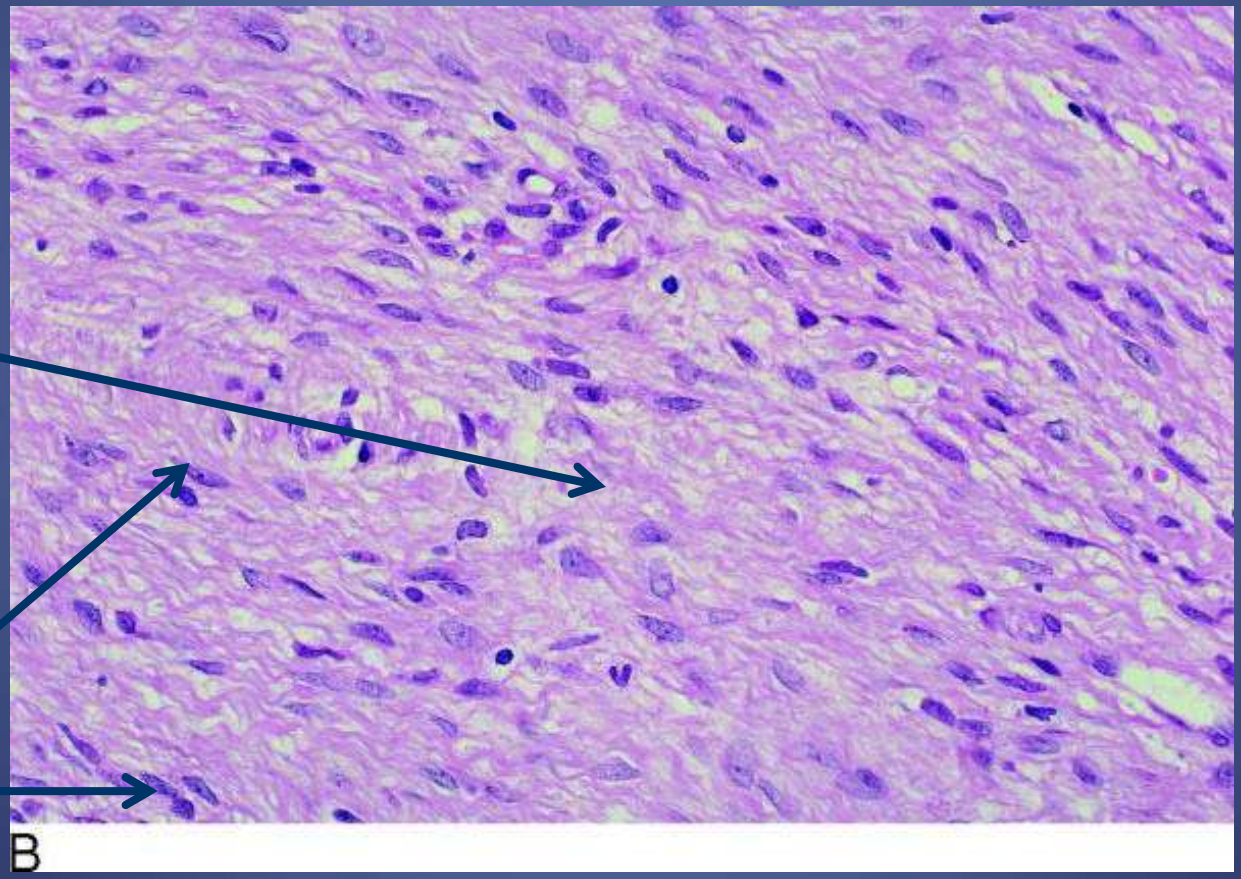

collagenous stroma

fibroblasts

Hemangioma

multilocular radiolucencies that have a characteristic soap bubble appearance

Hemangioma of bone showing honeycomb radiographic pattern with associated root resorption.

Hemangioma of bone. Note numerous vascular channels surrounded by trabeculae of bone.

trabeculae of bone.
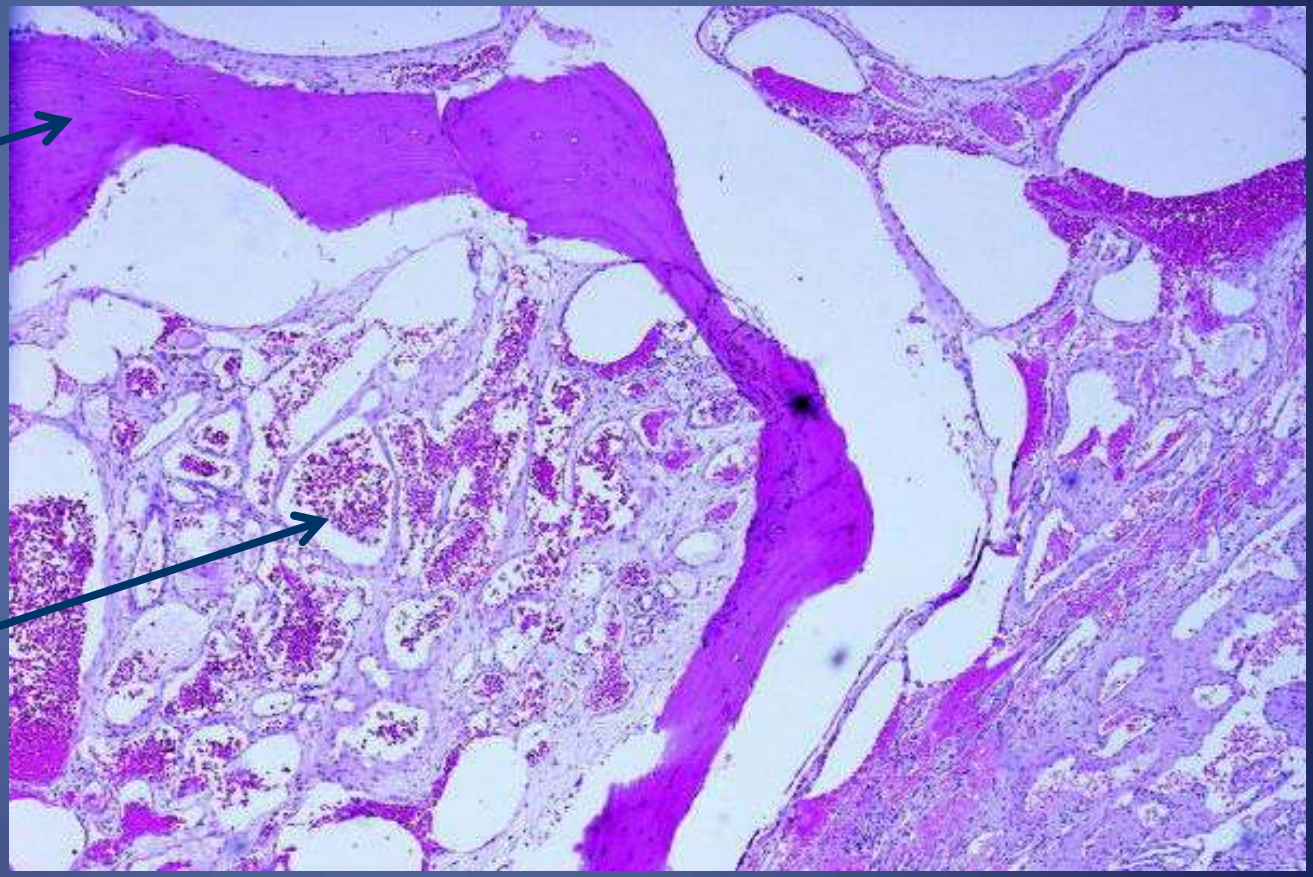
vascular channels